

Progress Reviews

Current Management of Amaurosis Fugax

The Amaurosis Fugax Study Group

We present a consensus on the pathophysiology, etiology, diagnosis, and treatment of amaurosis fugax. The phenomenon is defined and described, and the roles that extracranial and ocular vascular diseases play are discussed. Nonvascular ophthalmic and neurologic disorders that can be confused with amaurosis fugax are listed, and an algorithm for evaluation (which includes ophthalmic examination, laboratory studies, and noninvasive carotid artery studies) is given. Treatment of atherosclerosis, carotid artery disease, and other causes of amaurosis fugax are also discussed. (*Stroke* 1990;21:201–208)

Heightened interest in amaurosis fugax stimulated the organization of a symposium and the preparation of a review on this subject emphasizing newer information regarding pathogenesis, diagnosis, and treatment.¹ This article summarizes the collective current views of the authors, who represent the specialties of neurology, neuro-ophthalmology, ophthalmology, neurosurgery, hematology, and vascular surgery. The method of preparation of this article closely followed the practices used at National Institutes of Health consensus development conferences and is based on the belief that consensus formulation is a useful approach to controversial issues when the available data are inadequate to resolve difficult questions.

This document reflects the opinions of the Amaurosis Fugax Study Group, the members of which were selected to represent a balance and breadth of exper-

tise. While individual differences of opinion may exist regarding some of the statements in this report, the Group was able to achieve a consensus on all of the issues examined. We believe that these views are based on the available scientific data and that they may be useful to the practicing physician.

Pathophysiology—Definition and Description of the Phenomenon

Amaurosis fugax is defined as transient monocular visual loss attributed to ischemia or vascular insufficiency. Typically, patients describe diminished or absent vision in one eye that progresses over a few seconds and lasts for seconds to a few minutes.^{2–4} The impairment progressively may involve the entire visual field. The loss of vision usually begins in the upper field, less frequently in the periphery, and rarely in the lower field.⁵ Patchy and sectorial loss

From the Amaurosis Fugax Study Group: Henry J. M. Barnett, MD, The John P. Roberts Research Institute, London, Canada; Eugene F. Bernstein, MD, PhD, (Chairman, Amaurosis Fugax Study Group), Division of Vascular and Thoracic Surgery, Scripps Clinic and Research Foundation, La Jolla, California; Allan D. Callow, MD, PhD, Department of Surgery, Tufts University/New England Medical Center, Boston, Massachusetts; Louis R. Caplan, MD, Department of Neurology, Tufts University, Boston, Massachusetts; John E. Carter, MD, Division of Neurology and Ophthalmology, The University of Texas Medical School, San Antonio, Texas; Donald J. Dalessio, MD, Department of Medicine, Scripps Clinic and Research Foundation, La Jolla, California; Ralph B. Dille, MD, Division of Vascular and Thoracic Surgery, Scripps Clinic and Research Foundation, La Jolla, California; J. Donald Easton, MD, Department of Neurology, Brown University, Providence, Rhode Island; William K. Ehrenfeld, MD, Department of Surgery, University of California, San Francisco, San Francisco, California; William S. Fields, MD, Department of Neuro-oncology, The University of Texas System Cancer Center, Houston, Texas; Jean-Claude Gautier, Professor of Neurology, Service d'Urgences Cerebrovasculaires, Hopital de la Salpetriere, Paris, France; Laurence A. Harker, MD, Division of Hematology, Emory University School of Medicine, Atlanta, Georgia; Michael J. G. Harrison, DM, FRCP, The Reta Lila Weston Institute for Neurological Studies, University of London, London, United Kingdom; Sohan S. Hayreh, MD, PhD, Department of Ophthalmology,

The University of Iowa Hospitals and Clinics, Iowa City, Iowa; William F. Hoyt, MD, Department of Neurological Surgery, University of California, San Francisco, San Francisco, California; Joseph B. Michelson, MD, Division of Ophthalmology, Scripps Clinic and Research Foundation, La Jolla, California; Jay P. Mohr, MD, Department of Neurology, College of Physicians and Surgeons of Columbia University, New York, New York; Andrew N. Nicolaides, MS, FRCS, Department of Surgery, St. Mary's Hospital Medical School, London, United Kingdom; Shirley Otis, MD, Division of Neurology, Scripps Clinic and Research Foundation, La Jolla, California; Ralph W. Ross Russell, MD, FRCP, Department of Neurology, St. Thomas Hospital Medical School, London, United Kingdom; Peter J. Savino, MD, Neuro-ophthalmology Department, Wills Eye Institute, Philadelphia, Pennsylvania; Thoralf M. Sundt Jr., MD, Department of Neurologic Surgery, Mayo Clinic, Rochester, Minnesota; James F. Toole, MD, Department of Neurology, Wake Forest University, Winston-Salem, North Carolina; and Shirley H. Wray, MD, PhD, Department of Neurology, Harvard Medical School and Neurovisual Unit, Massachusetts General Hospital, Boston, Massachusetts.

Discussions leading to the preparation of this manuscript were funded by the Vascular Disease Foundation.

Address for reprints: Eugene F. Bernstein, MD, PhD, Scripps Clinic and Research Foundation, 10666 North Torrey Pines Road, La Jolla, CA 92037.

Received March 6, 1989; accepted August 15, 1989.

TABLE 1. Causes of Transient Monocular Blindness

<i>Embolic</i>
Carotid bifurcation thromboembolism
Great vessel or distal internal carotid artery atheroembolism
Cardiac emboli (valve, mural thrombi, intracardiac tumor)
Drug abuse-related intravascular emboli
<i>Hemodynamic</i>
Extensive atheromatous occlusive disease
Inflammatory arteritis (Takayasu's disease)
Hypoperfusion (cardiac failure; acute hypovolemia; systemic diseases disturbing blood viscosity, coagulability, or content)
<i>Ocular</i>
Anterior ischemic optic neuropathy
Central or branch retinal artery occlusion (often embolic)
Central retinal vein occlusion
Nonvascular causes (hemorrhage, pressure, tumor, congenital)
<i>Neurologic</i>
Brainstem, vestibular, and oculomotor
Optic neuritis, optic nerve or chiasm compression
Papilledema
Multiple sclerosis
Migraine
Psychogenic
<i>Idiopathic</i>

may also occur. Recurrent events tend to follow the same pattern.

The majority of attacks occur without obvious precipitating factors. Uncommonly, the visual loss lasts for several hours and yet full recovery occurs. Persistent visual loss after such an event is an indication of retinal or optic nerve infarction.

Etiology

Extracranial Cerebrovascular Disease

Thromboembolic. The visual disturbance in amaurosis fugax is a sudden episode of partial or complete monocular visual loss that lasts seconds to minutes, followed by complete recovery. Some of the attacks are considered to be due to embolism into the ophthalmic circulation from the ipsilateral common carotid artery and its branches, particularly in patients >50 years of age (Table 1). Amaurosis fugax may be an important marker of generalized atherosclerotic disease. The carotid atherosclerotic lesion may be an occlusion, a stenosis, or an irregular ulcerated lesion with or without stenosis.⁵⁻⁷ Stenosis of >75% may be associated with thrombus formation in the poststenotic cul-de-sac. Other carotid pathology responsible for the episode may include fibromuscular dysplasia, spontaneous dissection, and aneurysm of the carotid bifurcation. Material seen within the retinal arteries indicates embolism, and emboli may be seen even after vision has returned to normal. Bright, yellowish, glinting lipid emboli, so-called Hollenhorst plaques, are the most common emboli seen in the eye.⁸⁻¹⁰ The emboli most often are associated with atheromatous lesions of the

ipsilateral carotid artery or, less frequently, with atherosclerotic disease involving the aortic arch or the carotid siphon and contain cholesterol.¹¹ Isolated cholesterol crystals are observed occasionally. Pale or migrant emboli are composed of fibrin and platelets.¹² Calcific emboli, which are characteristically white and nonscintillating, may originate from the common carotid artery, more proximal arterial sites, or from calcific cardiac valvular disease.^{13,14} Amaurosis fugax associated with atherosclerotic occlusive disease may precede occlusion of the central retinal artery, occlusion of a branch retinal artery, or anterior ischemic optic neuropathy. Emboli of cardiac origin may reach the eye from valvular disease, such as rheumatic heart disease, mitral valve prolapse, marantic or infectious endocarditis, or calcific valvular disease. Patients with intracardiac lesions such as myxomas or mural thrombi (e.g., lesions associated with atrial fibrillation or myocardial infarction) usually have larger emboli that do not reach the eye. Retinal emboli from intravenous drug abuse may produce transient monocular visual loss, and talc or other foreign intravascular material may be seen on ophthalmoscopy.^{15,16}

Hemodynamic. Less frequently, amaurosis fugax may occur in patients with extensive atherosclerotic extracranial arterial occlusive disease, particularly involving several of the aortic arch branches. Visual loss under these circumstances is precipitated by a change in posture, by exercise, or by exposure to bright light and is due to retinal vascular insufficiency.^{17,18} The temporary hemodynamic episodes of monocular visual loss may be less rapid in onset than the brief transient attacks of embolic origin, with the visual loss developing over minutes rather than seconds and lasting slightly longer than embolic episodes. Recovery may take place more gradually. Symptoms of cerebral ischemia may coexist. The pattern of attacks in association with physical activity suggests a temporary inadequacy of the retinal circulation and retinal or chorioidal ischemia. Compensation becomes inadequate when both the external carotid artery and the internal carotid artery (ICA) are severely stenotic or occluded. In young women, the cause may be inflammatory arteritis (Takayasu's disease). Hypoperfusion due to low cardiac output or acute hypovolemia may cause amaurosis fugax that is usually bilateral. If unilateral, it is commonly associated with preexisting asymmetric occlusive vascular disease. Systemic diseases can alter ocular blood flow and produce transient monocular visual loss by disturbing blood viscosity, cellular blood content, or blood coagulability. Rarely, patients have retinal migraine with transient visual loss thought to be due to vasospasm in the retinal arterial system.¹⁹⁻²¹

Idiopathic. Some patients with monocular blindness have no demonstrable ocular or systemic explanation for their symptoms. At present, the cause in these patients must be considered idiopathic. In some of these patients the mechanism may be vasospastic.

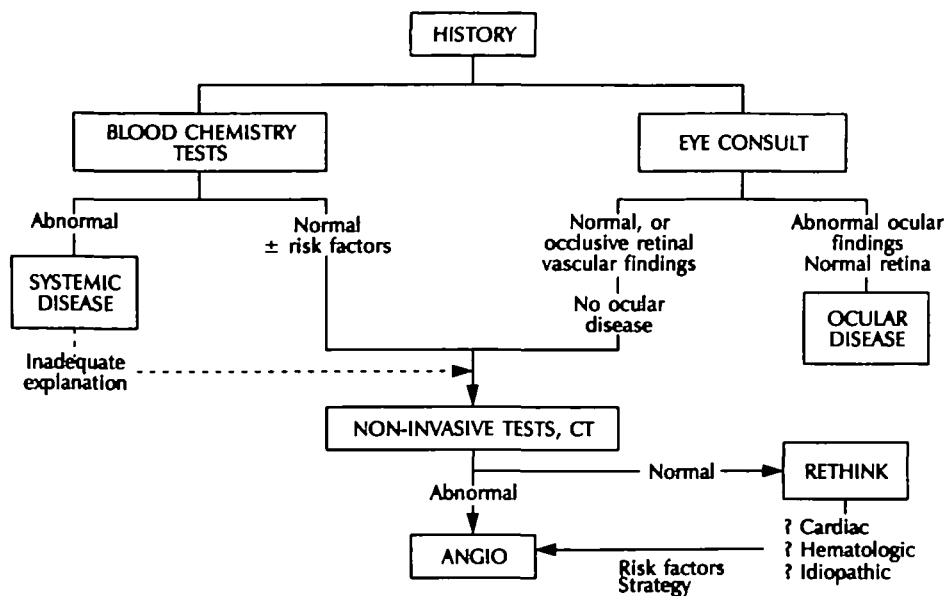


FIGURE 1. Diagnostic algorithm for workup of patients with transient monocular blindness. CT, computed tomography; ANGIO, angiography.

Ocular Vascular Diseases

Anterior ischemic optic neuropathy due to giant-cell arteritis, atherosclerosis, or thrombosis in situ affects persons ≥ 60 years of age and may produce amaurosis fugax. The visual loss is caused by severe narrowing or occlusion of the posterior ciliary arteries, with consequent acute ischemia of the optic nerve head.^{22,23} Fatigue, malaise, headache, and polymyalgia rheumatica often precede or accompany the visual symptoms.

Occlusion of the central retinal vein sometimes begins with attacks of amaurosis fugax due to transient slowing of the retinal arterial circulation produced by sudden occlusion of the central retinal vein. The fundoscopic findings in this condition are characteristic and include engorged retinal veins and multiple retinal hemorrhages.²⁴

Malignant arterial hypertension in some patients causes amaurosis fugax due to ischemia of the optic nerve head.²⁵ This is always accompanied by optic disk edema in addition to other ophthalmoscopic signs of hypertension. Headache, seizures, encephalopathy, and decreased renal function are also usually present.

Conditions That Can Be Confused With Amaurosis Fugax

Nonvascular ophthalmic disorders may present with transient monocular visual loss. Among these conditions are transient changes in the ocular media or intraocular pressure, such as vitreous floaters, vitreous hemorrhage, anterior chamber hemorrhage, and glaucoma.²⁶ Congenital anomalies of the optic disk, such as drusen or posterior staphyloma, also should be considered.²⁷ Intraorbital masses may produce gaze-evoked amaurosis fugax.^{28,29}

Neurologic disorders also can cause temporary visual loss that patients localize to one eye or do not localize precisely. Brainstem, vestibular, and oculo-

motor lesions cause blurred vision, usually with rotation, oscillation of objects, or diplopia. Intraorbital tumors, optic neuritis, and compression of the optic nerve or optic chiasm by aneurysms or tumors usually cause more gradual and persistent monocular visual loss. Patients with papilledema from any cause may note transient visual obscurations.³⁰ Multiple sclerosis and optic nerve damage may be accompanied by transiently decreased vision in one or both eyes after exercise or exposure to heat. Neurologic lesions, such as migraine, that affect postchiasmal visual pathways cause homonymous defects in the visual field that the patient may describe erroneously as monocular. Sequential eye closure tests for visual acuity and examination of the visual fields help localize the lesion. Scintillations, hallucinations, and the presence of other neurologic findings also identify a cerebral location. Visual loss also can be psychogenic.

Diagnostic Evaluation

Pace of the Evaluation

Because of the brief interval between the transient event and a stroke or blindness from temporal arteritis, the workup for transient monocular blindness should be undertaken without delay. In the absence of temporal arteritis, the outlook for vision is good, but the risk of stroke approaches that for hemispheric transient ischemic attack (TIA).^{31–36} Simultaneous evaluation of occult cardiac disease is justified by the high frequency of cardiac mortality among patients with this symptom.³⁷

An algorithm for the evaluation of transient monocular blindness is presented in Figure 1. The patient's history should help differentiate embolic amaurosis fugax from atypical visual spells due to a variety of other nonischemic mechanisms.³⁸

Ophthalmic Examination

A complete examination by an ophthalmologist or a neuro-ophthalmologist should seek evidence of unusual causes as well as those that support a diagnosis of embolic and retinal vascular disease.³⁹ Ocular signs of ischemia include occlusion of a branch retinal artery, regional retinal pallor, microinfarcts, and small hemorrhage(s).^{3,4,10,40,41} Distended, irregular veins and peripheral microaneurysms suggest retinal vascular insufficiency. These retinal vascular changes are best visualized by fluorescein angiography. Unusual detectable causes include narrow-angle glaucoma, intraocular hemorrhage, congenital anomaly of the optic disk, disk drusen, and orbital tumor.

Laboratory Studies

A few laboratory tests are recommended to detect associated systemic illnesses: a complete blood count for evidence of polycythemia or leukemia, a platelet count for evidence of thrombocytosis, a Westergren sedimentation rate for evidence of giant-cell arteritis, and screening for hyperlipidemia and diabetes mellitus.⁴²⁻⁴⁴ The value of a routine search for a prethrombotic state, with tests for the lupus anticoagulant and deficiencies in protein C, protein S, or antithrombin III, has not been established, but such tests are warranted in younger patients or those with systemic symptoms, known malignancy, or other systemic diseases.⁴⁵

Noninvasive Carotid Artery Studies

High-quality duplex ultrasound studies of the carotid artery are recommended strongly to identify occlusion, stenosis, or major ulceration at the carotid bifurcation and lesions of the proximal great vessels. If the results are positive, these studies are an indication for arch and carotid angiography.^{6,46-48} If the results of carotid duplex examination are normal or show only minor irregularities, evidence of intracranial stenosis at the level of the carotid siphon should be sought by pneumoplethysmography, ophthalmodynamometry or, particularly, transcranial Doppler examinations. Computed tomography or magnetic resonance imaging is recommended and may provide evidence of clinically silent cerebral embolism.⁴⁹⁻⁵²

If results of the duplex and intracranial tests show no abnormalities, renewed diagnostic efforts may be made. Under these circumstances, a fluorescein angiogram is advisable to document previous embolic occlusion, microinfarction, ischemia in the posterior ciliary arteries territory, or poor retinal perfusion since carotid angiography is usually inadequate to document ophthalmic artery disease.^{53,54}

When the results of a high-quality duplex study are normal, the morbidity associated with angiography must be balanced against the low yield of further information provided by angiography and the low risk of stroke in patients with normal duplex studies.⁵⁵⁻⁵⁷ Accordingly, routine carotid angiography is not rec-

ommended when the results of ultrasound examination are normal. Intravenous digital subtraction angiography is no longer indicated because of its low resolution.⁵⁸ Other imaging approaches, such as thrombus-directed imaging procedures with low density lipoproteins or labeled platelet studies and Doppler-documented plaque morphology to determine the activity of the carotid sinus mural thrombus, are not yet of established value.^{48,59} Ultrasonic documentation of plaque morphology is promising, but its role has not been defined yet.

When associated with carotid artery disease, amaurosis fugax is a marker of increased risk of death from myocardial infarction.³⁷ Therefore, patients in whom carotid atherosclerosis is demonstrated should have a cardiac assessment, both to identify cardiac sources of emboli and to detect those patients with ischemic heart disease.^{50,60,61}

At the end of the investigation, approximately 11% of patients <50 years of age will be found to have no cause for their visual loss and no history of migraine.⁶² Invasive procedures are not warranted in these patients, but careful follow-up is mandatory.⁶³

Treatment

Some ocular vascular diseases and conditions associated with amaurosis fugax have specific treatments. Especially important is the recognition and treatment of giant-cell arteritis and glaucoma. In addition, therapy is largely noncontroversial for the majority of other ocular vascular causes and the conditions that can be confused with amaurosis fugax. Emphasis here is directed to those conditions associated with occlusive vascular disease resulting in amaurosis fugax for which treatment is controversial or unproven.

Atherosclerosis

General comments. The efficacy of all forms of present therapy is uncertain because of insufficient data. Most reports of therapy lump together amaurosis fugax and cerebral hemispheric TIA, but the natural history of these two conditions may be different. The accepted primary implication is that amaurosis fugax caused by a carotid embolism is a precursor of hemispheric stroke.^{64,65} In a recent British study, the annual incidence rate of stroke in patients with this disorder was 2%,³⁴ four times that expected in a matched population sample, but the expected annual stroke rate after a hemispheric TIA is substantially greater.^{66,67} Blindness must also be considered a sequela of amaurosis fugax that may be prevented by treatment.

Carotid endarterectomy has been shown to be safe and effective in preventing stroke and blindness after amaurosis fugax in two recent reports.^{68,69} The combined mortality and permanent neurologic deficit rate in the experience of the University of California, San Diego, was 1.9%; at the Scripps Clinic it was 1.3%⁶⁸; and at the University of California, San Francisco, it was 3%.⁶⁹ Life table analysis of these patients following successful endarterectomy indi-

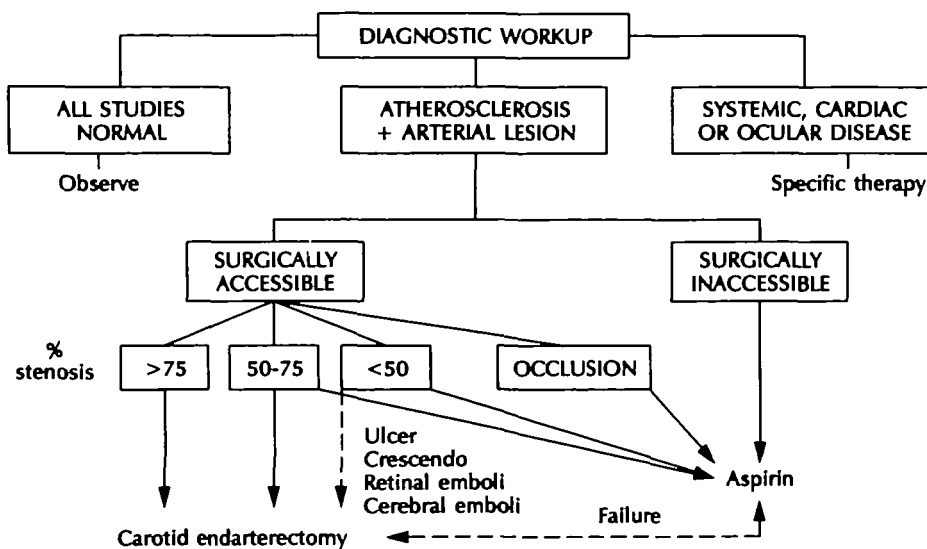


FIGURE 2. Suggested treatment plan for patients with transient monocular blindness.

states that at least 95% will be free of ipsilateral stroke for 8 years in all three series.^{68,69} However, results will vary from surgeon to surgeon.⁷⁰ Thus, the decision for surgical referral must be weighed against the morbidity and mortality rates of the individual surgeon involved, as well as against the natural history of the condition.

Aspirin reduces the prevalence of stroke plus death and of further TIA in patients with TIA.⁷¹⁻⁷⁴ Although the reduction in stroke alone has not been significant in most single studies, pooled data strongly suggest some benefit.⁷⁵ Patients with amaurosis fugax have constituted approximately 15% of the subjects of these trials, and it is assumed that the results of the trials apply to patients with amaurosis fugax as well as to those with hemispheric TIAs.

Several substantial clinical trials (of unstable angina,^{76,77} patency of saphenous vein grafts,⁷⁸ and TIA and minor stroke⁷⁹) have shown no difference in the effect of low (300–325 mg/day) versus high (900–1,300 mg/day) doses of aspirin, but a higher prevalence of side effects is associated with the high dose. For this reason, all recommendations at this time for aspirin are for 300–325 mg/day.

Dipyridamole and sulfinpyrazone have not been shown to confer additional benefit over aspirin alone in trials involving patients with TIA and minor stroke.^{73,75,80} Other nonsteroidal anti-inflammatory drugs or dipyridamole may have a place in the treatment of patients intolerant of aspirin.^{73,74,77} The combination of anticoagulant plus dipyridamole is used widely in patients with prosthetic heart valves.⁸¹

Anticoagulation. No conclusive evidence on its effect in patients with amaurosis fugax is available. Trials testing warfarin in the prevention of stroke and TIA in patients with TIA involved too few patients to be conclusive or statistically significant.^{66,82-85}

Modifiable risk factors for stroke should be addressed, with particular attention to hypertension, hypercholesterolemia, and smoking.

Carotid Artery Disease

The identification of plaque ulceration in patients with any of the categories of carotid stenosis may lead some physicians to a more aggressive approach in therapy because emboli of platelet-fibrin thrombi, atheromatous debris, and cholesterol crystals may be released from these ulcerated areas. Plaque appearance and composition (i.e., degree of ulceration, hemorrhage, calcification, and lipid deposition) may have important clinical implications and may affect thinking about appropriate therapy. The specific recommendations that follow are based on the degree of ICA stenosis or occlusion (Figure 2).

Occlusion. Transient attacks, either ocular or cerebral, are less common in patients with ICA occlusion than in those with ICA stenosis. Furthermore, amaurosis fugax may cease when a stenotic artery becomes occluded. Therefore, when a patient with amaurosis fugax is found to have a complete ICA occlusion, it is reasonable to treat the risk factors for carotid artery disease, give aspirin, and await developments. If amaurosis fugax continues, the cause may be embolism due to thrombus propagated from the carotid siphon or the occluded ICA stump traveling through external carotid collaterals. The cause also may be ischemia in a marginally perfused hemisphere or eye. Certain specific lesions associated with ICA occlusion and capable of producing amaurosis fugax can be corrected by surgery (e.g., external carotid artery ulceration or stenosis and ICA stump thrombosis with embolism).

Stenosis of >75% (surgically inaccessible site). In some patients, especially those with severe hypertension or diabetes mellitus, carotid atheroma may be diffuse or localized at an inaccessible site (usually in the carotid artery siphon) with or without accompanying disease at the carotid bifurcation. In this group, aspirin therapy combined with general measures against the underlying disease and risk factors are recommended. Some clinicians prefer anticoagulation if hypertension can be controlled.

Stenosis of >75% (surgically accessible site). High degrees of stenosis appear to be associated with an increased risk stroke. Intraluminal thrombi seen on angiography also may occur in patients with this degree of stenosis, and the risk that a high-grade stenosis will proceed to occlusion is substantial. Carotid endarterectomy appears to be the treatment of choice when performed by a qualified surgeon in a patient with reasonable risk factors for surgery. Carotid endarterectomy should be accompanied by aspirin and treatment of risk factors for carotid artery disease.

Stenosis of 50–75%. The risk of stroke in patients with amaurosis fugax and moderate ICA stenosis is probably lower than in those with a severe stenosis. Therapy for these patients is particularly controversial, in part because of the variability of measurements of stenoses (e.g., percentage reduction in diameter or percentage reduction in cross-sectional area), which prevent the comparison of data across studies. Patients with moderate stenosis should be considered for carotid endarterectomy. Aspirin therapy has also been shown to reduce the risk of myocardial infarction and stroke and should be prescribed.

Stenosis of <50%. Therapy for patients with <50% stenosis is controversial because of the absence of firm data about the balance of risks and benefits of carotid surgery in this group. Pending such data, these patients should be treated with aspirin, with or without carotid endarterectomy.

Factors favoring consideration of endarterectomy in patients with <75% ipsilateral ICA stenosis include crescendo amaurosis fugax, associated TIA or minor stroke, evidence of cerebral infarction on computed tomography, retinal emboli observed on ophthalmoscopy, and ulceration of the carotid bulb. Failure of aspirin therapy among these patients suggests the need for reconsideration of endarterectomy or anticoagulation, particularly in the presence of ulceration. The pressure of fresh thrombus suggests consideration of anticoagulation, followed by later endarterectomy when the thrombus has resolved.

Therapeutic Failure

Medical failure. If patients continue to have episodes of amaurosis fugax while taking aspirin, reevaluation of the possibility that the atherosclerotic process has worsened is important. If the disease has progressed to severe stenosis, surgical therapy may be indicated. If no change has occurred, aspirin may be continued or anticoagulation may be initiated.

Surgical failure. If the episodes continue after endarterectomy, other possibilities, such as inadequate surgical removal of plaque, restenosis, or a tandem lesion that may be serving as a source of microemboli to the eye, must be considered. Therapy must be individualized.

Other Entities

Cardioembolism. A cardiac cause requires the appropriate therapy, for example, anticoagulation for mural thrombus, aspirin for mitral valve prolapse, or cardiac surgery, as indicated after thorough cardiac assessment.

Giant-cell arteritis. If the sedimentation rate is elevated, patients with amaurosis fugax alone or accompanied by other symptoms suggesting giant-cell arteritis should be placed on high-dose corticosteroids to prevent visual loss secondary to anterior ischemic optic neuropathy or a central retinal artery occlusion. The patients then should be referred for consultation regarding further ocular evaluation and temporal artery biopsy. Further management should be based on the outcome of this evaluation.

Migraine. A few patients with migraine are stroke-prone. Generally, such patients have complicated migraine or uncomplicated migraine associated with risk factors for atherosclerosis (e.g., hypertension, hyperlipidemia, cigarette smoking) or with other risk factors for stroke (e.g., use of oral contraceptives, the puerperium). Patients <40 years of age who have amaurosis fugax and uncomplicated migraine appear to require no treatment for the amaurosis fugax, but oral contraceptives and cigarette smoking should be avoided. Patients who are >40 years of age or who have complicated migraine or other risk factors for stroke should be treated with 300–325 mg aspirin/day, and vasoconstrictor agents should be avoided.

Idiopathic. Patients <40 years of age who have typical amaurosis fugax without any obvious cause appear to be at very low risk for subsequent stroke or permanent visual loss; such patients require no treatment, but a history of drug abuse should be sought. Those >40 years of age are probably at higher risk and probably should be treated with 300–325 mg aspirin/day. In addition, efforts should be made to modify their risk factors for atherosclerosis. If their episodes of amaurosis fugax become frequent or prolonged, the diagnosis should be reconsidered, as should the need for further evaluation, particularly a search for a cardioembolic source.

Conclusion

These recommendations for treatment represent the current preferred practice by most members of the Amaurosis Fugax Study Group. Changes in preference may evolve with more and better data acquisition in the near future, particularly from current multicenter clinical trials. Until the results of current surgical trials are known, these recommendations are only an account of present-day belief and practice.

References

- Bernstein EF (ed): *Amaurosis Fugax*. New York, Springer-Verlag, 1988
- Ashby M, Oakley N, Lorentz I, Scott D: Recurrent transient monocular blindness. *Br Med J* 1963;2:894–897

3. Fisher CM: Transient monocular blindness associated with hemiplegia. *Am Arch Ophthalmol* 1952;47:167-203
4. Ross Russell RW: Observations on the retinal blood vessels in monocular blindness. *Lancet* 1961;2:1422-1428
5. Wilson LA, Ross Russell RW: Amaurosis fugax and carotid artery disease: Indications for angiography. *Br Med J* 1977; 2:435-437
6. Pessin MD, Duncan GW, Mohr JP, Poskauer DC: Clinical and angiographic features of carotid transient ischemic attacks. *N Engl J Med* 1977;296:358-362
7. Parkins PJ, Kendall BD, Marshall J, McDonald WI: Amaurosis fugax: Some aspects of management. *J Neurol Neurosurg Psychiatry* 1982;45:1-6
8. Hollenhorst RW: Significance of bright plaques in the retinal arterioles. *JAMA* 1961;178:123-129
9. Hollenhorst RW: Vascular status of patients who have cholesterol emboli in the retina. *Am J Ophthalmol* 1966;81: 1159-1165
10. Ross Russell RW: Atheromatous retinal embolism. *Lancet* 1963;2:1354-1356
11. David NJ, Klintworth GK, Frieberg SJ, Dillon M: Fatal atheromatous cerebral embolism associated with bright plaques in the retinal arterioles. *Neurology* 1963;13:708-713
12. Fisher CM: Observations of the fundus oculi in transient monocular blindness. *Neurology* 1959;9:333-347
13. Arruga J, Sanders MD: Ophthalmologic findings in seventy patients with evidence of retinal embolism. *Ophthalmology* 1982;89:1336-1345
14. Brockmeier LB, Adolph RJ, Gustin BW, Holmes JC, Sacks JG: Calcium emboli to the retinal artery in calcific aortic stenosis. *Am Heart J* 1981;101:32-37
15. Michelson JB, Whitcher JP, Wilson S, O'Connor GR: Foreign body granuloma of the retina associated with intravenous cocaine addiction. *Am J Ophthalmol* 1979;87:278-282
16. Atlee WE: Talc and corn starch emboli in the eyes of drug abusers. *JAMA* 1972;219:49-51
17. Ross Russell RW, Page NGR: Critical perfusion of brain and retina. *Brain* 1983;106:419-427
18. Furlan AJ, Whisnant JP, Kessing JP: Unilateral visual loss in bright light: An unusual symptom of carotid artery occlusive disease. *Arch Neurol* 1979;36:675-676
19. Carroll D: Retinal migraine. *Headache* 1970;10:9-13
20. Krapin D: Occlusion of the central retinal artery in migraine. *N Engl J Med* 1964;270:359-360
21. Coppetto JR, Lessell S, Sciarra R, Bear L: Vascular retinopathy in migraine. *Neurology* 1986;36:267-270
22. Hayreh SS: Anterior ischaemic optic neuropathy. I. Terminology and pathogenesis. *Br J Ophthalmol* 1974;58:955-989
23. Hayreh SS: *Anterior Ischemic Optic Neuropathy*. New York, Springer-Verlag, 1975
24. Hayreh SS: So-called "central retinal vein occlusion": I. Pathogenesis, terminology, clinical features. *Ophthalmologica* 1976;172:1-13
25. Hayreh SS, Servais GE, Viridi PS: Fundus lesions in malignant hypertension, V. hypertensive optic neuropathy. *Ophthalmology* 1986;93:74-87
26. Ravitz J, Seybold ME: Transient monocular visual loss from narrow angle glaucoma. *Arch Neurol* 1984;41:991-993
27. Seybold ME, Rosen PN: Peripillary staphyloma and amaurosis fugax. *Ann Ophthalmol* 1977;9:1139-1141
28. Brown GC, Shields JA: Amaurosis fugax secondary to presumed cavernous hemangioma of the orbit. *Ann Ophthalmol* 1981;13:1205-1209
29. Wilkes SR, Troutmann JC, DeSanto LW, Campbell RJ: Osteoma. An unusual cause of amaurosis fugax. *Mayo Clin Proc* 1979;54:258-260
30. Hayreh SS: Optic disc edema in raised intracranial pressure: IV. Associated visual disturbances and their pathogenesis. *Arch Ophthalmol* 1977;95:1566-1579
31. Marshall J, Meadows S: The natural history of amaurosis fugax. *Brain* 1968;91:419-434
32. Hooshmand H, Vines FS, Lee HM, Grindal A: Amaurosis fugax: Diagnostic and therapeutic aspects. *Stroke* 1974; 5:643-647
33. Pfaffenbach DD, Hollenhorst RW: Morbidity and survivorship of patients with embolic cholesterol crystals in the ocular fundus. *Am J Ophthalmol* 1973;75:66
34. Poole CJM, Ross Russell RW: Mortality and stroke after amaurosis fugax. *J Neurol Neurosurg Psychiatry* 1985; 48:902-905
35. Warlow CP: Transient ischemic attacks, in Matthews WB, Glaser GH (eds): *Recent Advances in Clinical Neurology*. Edinburgh, Churchill Livingstone, 1982, pp 191-214
36. Hurwitz BJ, Heyman A, Wilkinson WE, Haynes CS, Utley CM: Comparison of amaurosis fugax and transient cerebral ischemia: A prospective study. *Ann Neurol* 1985;18:698-705
37. Muuronen A, Kaste M: Outcome of 314 patients with transient ischemic attacks. *Stroke* 1982;13:24-31
38. Hachinski VC, Porchawka J, Steel JC: Visual symptoms in the migraine syndrome. *Neurology* 1973;23:570-579
39. Dyll DM, Margolis M, David JH: Amaurosis fugax. Fundoscopic and photographic observations during an attack. *Neurology* 1966;16:136
40. Wolpaw ER, Lupton RG: Transient vertical monocular hemianopia with anomalous retinal artery branching. *Stroke* 1981; 12:691-692
41. Gerstenfeld J: The fundus oculi in amaurosis fugax. *Am J Ophthalmol* 1964;58:198-205
42. Levin J, Swanson PD: Idiopathic thrombocytosis. A treatable cause of transient ischemic attacks. *Neurology* 1968;18:711-713
43. Wagener HP, Hollenhorst RW: The ocular lesions of temporal arteritis. *Am J Ophthalmol* 1958;45:617-630
44. Dandona P, Bolger JP, Boag F, Fonseca V, Abrams JD: Proliferative retinopathy and diabetes mellitus (letter). *Lancet* 1984;1:1294
45. Smith DB: Protein C deficiency: A cause of amaurosis fugax. *J Neurol Neurosurg Psychiatry* 1987;50:361-362
46. Gaul JJ, Marks SJ, Weinberger J: Visual disturbance and carotid artery disease: 500 symptomatic patients studied by non-invasive carotid artery testing including B-mode ultrasonography. *Stroke* 1986;17:393-398
47. Lees RB, Kistler JP, Sanders D: Duplex doppler scanning and spectral bruit analysis for diagnosing carotid stenosis. *Circulation* 1982;66(suppl):102-105
48. Wolverson MK, Bashiti HM, Peter GJ: Ultrasonic tissue characterization of atheromatous plaques using a high-resolution real-time scanner. *Ultrasound Med Biol* 1983; 6:669-709
49. Awad I, Modic M, Little JR, Furlan AJ, Weinstein M: Focal parenchymal lesions in transient ischemic attacks: Correlation of computed tomography and magnetic resonance imaging. *Stroke* 1986;17:399-403
50. DiBono DP, Warlow CP: Potential sources of emboli in patients with presumed transient cerebral or retinal ischemia. *Lancet* 1981;1:343-345
51. Perronee P, Candelise L, Scotti G, De Grandi C, Scialfa G: CT evaluation in patients with transient ischemic attack: Correlation between clinical and angiographic findings. *Eur Neurol* 1979;18:217-221
52. Sipponen JT, Kaste M, Sepponen RE, Kuurne T, Suoranta H, Sivula A: Nuclear magnetic resonance imaging in reversible cerebral ischaemia. *Lancet* 1983;1:294-295
53. Muci-Mendosa R, Arruga J, Edward WO, Hoyt WF: Retinal fluorescein angiographic evidence for atheromatous microembolism. *Stroke* 1980;11:154-158
54. Weinberger J, Bender AN, Yang WC: Amaurosis fugax associated with ophthalmic artery stenosis: Clinical simulation of carotid artery disease. *Stroke* 1980;11:290-293
55. Earnest F, Forbes G, Sandok BA, Whisnant J: Complications of cerebral angiography: Prospective assessment of risk. *AJNR* 1983;4:1191-1199
56. Edwards JH, Kricheff II, Riles T, Imparato A: Angiographically undetected ulceration of the carotid bifurcation as a cause of embolic stroke. *Radiology* 1979;132:369-373
57. Eikelboom C, Riles TR, Mintzer R, Baumann FG, DePhillip G, Lin J, Imparato AM: Inaccuracy of angiography in the diagnosis of carotid ulceration. *Stroke* 1983;14:882-885

58. Ludwig JW, Verhoeven LHJ, Engels PHC: Digital video subtraction angiography (DVSA) equipment. Angiographic technique in comparison with conventional angiography in different vascular areas. *Br J Radiol* 1982;55:545-553
59. Lees RS, Lees AM, Strauss WH: External imaging of human atherosclerosis. *J Nucl Med* 1983;24:154-156
60. Brockmeier LB, Adolph RJ, Gustin BW, Holmes JC, Sacks JG: Calcium emboli to the retinal artery in calcific aortic stenosis. *Am Heart J* 1981;101:32-37
61. Caltrider ND, Irvine AR, Kline HJ, Rosenblatt A: Retinal embolism in patients with mitral valve prolapse. *Am J Ophthalmol* 1980;90:534-539
62. Eadie MJ, Sutherland JM, Tyrer JH: Recurrent monocular blindness of uncertain cause. *Lancet* 1968;1:319-321
63. Goodwin JA, Gorelick PB, Helgason CM: Symptoms of amaurosis fugax in atherosclerotic carotid artery disease. *Neurology* 1987;37:829-832
64. Morax PV, Aron Rosa D, Gautier JC: Symptoms et signes ophtalmologiques des stenoses et occlusions carotidiennes. *Bull Soc Ophthalmol Francais* 1970;1:169-174
65. Parkin PH, Kendall BE, Marshall J, McDonald WI: Amaurosis fugax: Some aspects of management. *J Neurol Neurosurg Psychiatry* 1982;45:1-6
66. Easton JD, Hart RG, Sherman DH, Kaste M: Diagnosis and management of ischemic stroke. Part I. Threatened stroke and its management. *Curr Probl Cardiol* 1983;8:1-76
67. Whisnant JP, Matsumoto N, Elveback LR: Transient cerebral ischemic attacks in a community. *Mayo Clin Proc* 1973;48:194-198
68. Bernstein EF, Dilley RB: Late results following carotid endarterectomy for amaurosis fugax. *J Vasc Surg* 1987;6:333-340
69. Connelly DP, Okuhn S, Ehrenfeld WK: Longterm results of surgical therapy for amaurosis fugax, in Bernstein EF (ed): *Amaurosis Fugax*. New York, Springer-Verlag, 1988, pp 273-285
70. Fode NC, Sundt TM Jr, Robertson JT, Peerless SJ, Shields CB: Multicenter retrospective review of results and complications of carotid endarterectomy in 1981. *Stroke* 1986;17:370-376
71. Fields WS, Lemak NA, Frankowski RF, Hardy RJ: Controlled trial of aspirin in cerebral ischemia. *Stroke* 1977;8:301-316
72. Fields WS, Lemak NA, Frankowski RF, Hardy RJ: Controlled trial of aspirin in cerebral ischemia, Part II. *Stroke* 1978;9:309-319
73. Canadian Cooperative Study Group: A randomized trial of aspirin and sulfinpyrazone in threatened stroke. *N Engl J Med* 1978;299:53-59
74. Boussier MG, Eschwege E, Haguenu M, Lefavconnier JM, Thibault N, Touboul D, Touboul PJ: "AICLA" controlled trial of aspirin and dipyridamole in the secondary prevention of atherothrombotic cerebral ischemia. *Stroke* 1983;14:5-14
75. Antiplatelet Trialists Collaboration. Secondary prevention of vascular disease by prolonged antiplatelet therapy. *Br Med J* 1988;296:320-331
76. Lewis HD Jr, Davis JW, Archibald DG, Steinke WE, Smitherman TC, Dougherty JE, Schnaper HW, Le Winter MH, Linares E, Pouget TM, Sabbarwal SC, Chester E, DeMots H: Protective effects of aspirin against acute myocardial infarction and death in men with unstable angina. Results of a Veterans Administration cooperative study. *N Engl J Med* 1983;309:396-403
77. Cairns JA, Gent M, Singer J, Finne KJ, Frogatt GM, Holder DA, Jablousky G, Kostuk WJ, Melendez LJ, Myers MG, Sackett DL, Sealey BJ, Tanser PH: Aspirin, sulfinpyrazone or both in unstable angina: Results of a Canadian multicenter trial. *N Engl J Med* 1985;313:1369-1375
78. Lorenz RL, Weber M, Kotzur J, Theisen K, Schacky CV, Meister W, Reichardt B, Weber PC: Improved aorto-coronary bypass patency by low-dose aspirin (100 mg daily). Effects on platelet aggregation and thromboxane formation. *Lancet* 1984;1:1261-1264
79. UK-TIA Study Group: Design and protocol of the UK-TIA Aspirin Study, in Tognoni G, Garattini S (eds): *Drug Treatment and Prevention in Cerebrovascular Disorders. Clinical Pharmacology and Drug Epidemiology*. Amsterdam, Elsevier, 1979, vol 2, p 387
80. American-Canadian Cooperative Study Group: Persantine aspirin trial in cerebral ischemia. Part II: Endpoint results. *Stroke* 1985;16:406-415
81. Sullivan JM, Harken DE, Gorlin R: Pharmacologic control of thromboembolic complications of cardiac valve replacement. *N Engl J Med* 1971;284:1391-1394
82. Veterans Administration Cooperative Study of Atherosclerosis, Neurology Section: An evaluation of anticoagulant therapy in the treatment of cerebrovascular disease. *Neurology* 1961;11(pt II):132-138
83. Pearce JMS, Gubbay SS, Walton J: Long-term anticoagulant therapy in transient cerebral ischemic attacks. *Lancet* 1965;1:6-9
84. Baker RN, Broward JA, Fang HC, Fisher CM, Groch SN, Heyman A, Karp HR, McDevitt E, Scheinberg P, Schwartz W, Toole JF: Anticoagulant therapy in cerebral infarction. *Neurology* 1962;12:823-835
85. Baker RN, Schwartz W, Rose AS: Transient ischemic attacks—A report of a study of anticoagulant treatment. *Neurology* 1966;16:841-847

KEY WORDS • amaurosis fugax • cerebrovascular disorders • diagnosis

Current management of amaurosis fugax. The Amaurosis Fugax Study Group.

Stroke. 1990;21:201-208

doi: 10.1161/01.STR.21.2.201

Stroke is published by the American Heart Association, 7272 Greenville Avenue, Dallas, TX 75231

Copyright © 1990 American Heart Association, Inc. All rights reserved.

Print ISSN: 0039-2499. Online ISSN: 1524-4628

The online version of this article, along with updated information and services, is located on the
World Wide Web at:

<http://stroke.ahajournals.org/content/21/2/201>

Permissions: Requests for permissions to reproduce figures, tables, or portions of articles originally published in *Stroke* can be obtained via RightsLink, a service of the Copyright Clearance Center, not the Editorial Office. Once the online version of the published article for which permission is being requested is located, click Request Permissions in the middle column of the Web page under Services. Further information about this process is available in the [Permissions and Rights Question and Answer](#) document.

Reprints: Information about reprints can be found online at:
<http://www.lww.com/reprints>

Subscriptions: Information about subscribing to *Stroke* is online at:
<http://stroke.ahajournals.org/subscriptions/>